



**Case Report**

**Familial haemophagocytic lymphohistiocytosis: rare cause of acute liver failure in a neonate--a case report**

**Rahul Ojha\*\* FRACP, Sayed Zia\*\* MRCP, Fauwaz Al-Kasim\*\* MRCP and Abdul Rehman Al-Hussaini A\*\* FRACP**

**\*Sydney Medical School Nepean, The University of Sydney, NSW, Australia**

**\*\*Children's Hospital, Riyadh Medical Complex, Riyadh, Kingdom of Saudi Arabia**

*(Received 10 November 2012 and accepted 22 May 2013)*

**ABSTRACT:** Familial haemophagocytic lymphohistiocytosis (FHLH) is a rare life-threatening disorder of the immune system characterized by proliferation and infiltration of hyperactivated macrophages and T-lymphocytes and manifesting as acute illness with prolonged fever, cytopenias, and hepatosplenomegaly. We describe a one-month-old female with FHLH and rapidly progressing liver failure. To conclude, FHLH should be included in the differential diagnosis of acute liver failure in neonates and young infants.

**KEY WORDS:** *Familial haemophagocytic lymphohistiocytosis; Acute liver failure; Neonate; Case report*

**INTRODUCTION**

Familial haemophagocytic lymphohistiocytosis (FHLH) is a rare autosomal recessive disease that occurs in early infancy in 70% of cases. FHLH is characterised by organ infiltration by phagocytosing histiocytes, and caused by hyper-inflammatory syndrome because of hyper-cytokinaemia of pro-inflammatory mediators released by stimulated lymphocytes and histiocytes. The etiology is well established through identification of three causative genetic mutations till date<sup>1</sup>. In one study, mutation analysis was performed in seven neonates who were suspected to have HLH. Out of the seven, three neonates had UNC13D gene mutation and two had Perforin gene mutation<sup>2</sup>.

Here we present a neonate with FHLH and rapidly progressing liver failure. Some cases are thought to be associated with viral infections, others manifest a familial inheritance. When untreated the disease is uniformly fatal.

**CASE DETAILS**

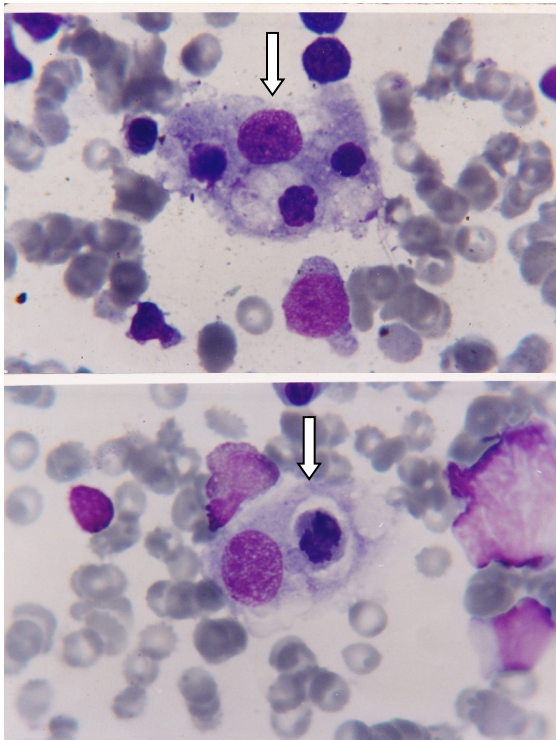
A one month old Syrian female, a product of full term pregnancy with a birth weight of 3.5 kg from consanguineous parents, presented with history of fever and poor feeding for 2 days. Immediate neonatal period was uneventful. Family history revealed death of a sibling at the age of 6 weeks secondary to a similar illness and an undiagnosed liver disease.

Initial physical examination on admission revealed a sick, pale, non-icteric baby, with temperature of 39°C, respiratory rate 50/min, pulse rate 145/min and blood pressure 65/40 mmhg. Liver edge was 5 cm below right costal margin, with a span of 11 cm, firm in consistency, non-tender, and no audible bruit. Spleen was 6cm below left costal margin. There was no evidence of ascites. There were a few enlarged lymph nodes at the axillae and inguinal regions. Other systemic examination was unremarkable.

Over the first week in hospital, the baby developed ascites, progressive direct hyperbilirubinemia (Total serum bilirubin/ Direct bilirubin = 126/96 umol/L), liver dysfunction (Alanine aminotransferase = 193U/L, Serum Albumin = 25 gm/L, INR = 2.3, PPT = 60 sec and ammonia = 83umol/L), anaemia (Haemoglobin = 8gm/L), leucopenia (White blood cell = 2500/), neutropenia (<1000/cm<sup>3</sup>), and thrombocytopenia (<100,000/cm<sup>3</sup>).

**Correspondence at:** Department of General Paediatrics, Nepean Hospital. Lecturer, Sydney Medical School Nepean, The University of Sydney, NSW, Australia; Cell: +61-2-47342134; Email: [ojharahul@yahoo.co.in](mailto:ojharahul@yahoo.co.in)

Further laboratory testing revealed serum triglycerides 3.2 mmol (Normal <2.2 mmol), serum lactic dehydrogenase 1360 M/L (Normal 230-460 M/L) and serum fibrinogen 0.5 g/l (Normal > 1.5 g/l). Extensive viral serologic work up for Epstein Barr virus, cytomegalovirus, rubella, hepatitis viruses A, B and C, parvovirus, echo virus, and HIV was negative. Screening tests for toxoplasmosis and syphilis were also negative. Iron profile showed the following: serum iron 36.4 umols/L (Normal 6-27), possibly because the baby received blood transfusion, total iron binding capacity > 117.3 umol/L (Normal 53-92), S.Ferritin 8408 ng/ml (Normal 13-150 ng/ml). Hormonal investigations revealed morning cortisol level 851.5 nmols/L (Normal 171-536) and serum thyroid stimulating hormone 0.213 mlu/L (Normal 0.27-4.2 mlu/L). Red blood cells Galactose 1 phosphate Uridyl transferase was 28.4 ugm (Normal 18-28.5 ugm). Metabolic work-up included urine for organic acids and plasma for amino acids, both were unremarkable. Bone marrow aspirate and biopsy showed increased macrophages with haemophagocytosis (**Figure 1**), increased histiocytes and no blast cells. Based on the above investigations a diagnosis of FHLH was made.



**Figure 1: Phagocyte cell engulfing red blood cells in bone marrow (Arrow).**

The baby persisted to spike temperatures from 39°C to 40°C despite repeatedly negative septic work-up and intravenous antibiotics. The liver failure worsened and supportive treatment with blood products, nutritional support with medium-chain triglyceride (MCT) formula, lactulose and

diuretics were initiated. Unfortunately, the baby died before transfer to a centre with facility for bone marrow transplantation, three weeks after admission to the hospital.

## DISCUSSION

Haemophagocytic syndrome is a reactive disorder of the mononuclear phagocytic system, characterised by histiocytic proliferation with marked Haemophagocytosis<sup>3</sup>. This syndrome encompasses both primary (Familial) and secondary forms. FHLH is rare AR disorder and have poor prognosis and tends to occur in early infancy<sup>4</sup>. Many studies have reported Familial HLH in preterm neonates. Levendoglu-Tugal et al<sup>5</sup> reported 4 preterm infants with HLH. These 4 preterm later developed NEC (Necrotising Enterocolitis)<sup>5</sup>. Uchiyama et al in another study reported fatal HLH in extremely low birth infants<sup>6</sup>. Acquired HLH mostly occurs in older children and adolescents<sup>7</sup>.

The development of HLH is possibly associated with an underlying immune disorder that results in the uncontrolled activation of the cellular immune system and excessive release of pro-inflammatory mediators like tumour necrosis factor alpha (TNF- $\alpha$ ), interleukin (IL), interferon alpha (INF- $\alpha$ ), giving rise to the term cytokine disease or macrophage syndrome<sup>8</sup>. Patients with HLH exhibit impairment of their Natural Killer cells (NK). FHLH results from mutation of a protein that mediates the cytotoxic activity of NK cells and T cells called perforin with a locus on chromosome 10<sup>9</sup>.

Because of the relative rarity of the disorder as well as unfamiliarity on the part of clinicians, the diagnosis can be elusive even with a classical presentation because on one hand it can mimic sepsis by demonstrating hepatosplenomegaly, persistent fever, CNS involvement and cytopenias<sup>10</sup>, while on other hand it can mimic liver failure<sup>11,12</sup>.

Diagnosis must be based on clinical, histological and additional laboratory findings (**Table 1**)<sup>13</sup>. Our patient manifested a classical presentation of FHLH. Such manifestations of HLH can be confused with sepsis, pyrexia of unknown origin, hepatitis or malignancy<sup>14</sup>. In our case, extensive septic and viral serologic work-up was unrevealing, which is not unusual in FHLH as compared to acquired HLH.

HLH of infancy and childhood are invariably fatal if not treated. Early recognition and treatment is necessary to prevent disease progression. The immediate aim of treatment is to suppress the severe inflammation that is responsible for the life-threatening symptoms. Agents like corticosteroids, cyclosporine and etoposide can achieve this aim. Remission has been reported using chemotherapy and immunomodulators<sup>15</sup>. The ultimate aim must

be to exchange the defective immune system with normally functioning immune effector cells, which can only be achieved by hematopoietic stem cell transplant<sup>16</sup>.

First success with bone marrow transplant was in 1986 using a healthy matched sibling donor. Ten years later, Dr Maurizio Arico and his colleagues at the Histiocytic Society supported results from the International HLH Registry, which showed that greater than 60% of the children with HLH who had a matched sibling transplant were alive after 5 years as compared to only 10% of children with HLH who had received chemotherapy alone<sup>17</sup>. Shah et al have reported a patient who received

postnatal hematopoietic stem cell transplantation for HLH after receiving *in utero* chemotherapy for disease stabilisation<sup>18</sup>. Jabado et al reported 48 patients from a single center, who underwent successful hematopoietic stem cell transplantation from HLA genetically nonidentical donors<sup>19</sup>. The best results have been seen in children who respond well to HLH chemotherapy protocol prior to BMT, emphasizing the importance of pretransplant control. National bone marrow donor program in the US reported that patients who entered a BMT procedure with active systemic or CNS disease had a very poor long-term outcome<sup>20</sup>.

**Table 1: Revised diagnostic criteria for HLH<sup>13</sup>**

|   |  |
|---|--|
| The diagnosis HLH can be established if one of either 1 or 2 below of the following criteria are fulfilled: |  |
| 1.  | A molecular diagnosis consistent with HLH.   |
| 2.  | Diagnostic criteria for HLH fulfilled (five of the eight criterias below):               |
| <i>Initial diagnostic criteria (to be evaluated in all patient with HLH)</i>                                |  |
| I.  | Fever  |
| II.   | Splenomegaly   |
| III.  | Cytopenias (affecting $\geq 2$ of 3 lineages in the peripheral blood):                   |
|   | i. Haemoglobin $< 90\text{g/L}$ (in infants $< 4$ weeks: haemoglobin $< 100\text{g/L}$ ) |
|   | ii. Platelets $< 100 \times 10^9/\text{L}$   |
|   | iii. Neutrophil $< 1.0 \times 10^9/\text{L}$   |
| IV.   | Hypertriglyceridaemia and /or hypofibrinogenemia:  |
|   | i. Fasting triglycerides $\geq 3\text{mmol/L}$ i.e. ( $\geq 265\text{mg/dl}$ )           |
|   | ii. Fibrinogen $\leq 1.5\text{g/L}$  |
| V.  | Haemophagocytosis in bone marrow or spleen or lymph nodes.                               |
| VI.   | No evidence of malignancy.   |
| <i>New diagnostic criteria</i>  |  |
| I.  | Low or absent NK-Cell activity (according to local laboratory reference).                |
| II.   | Ferritin $\geq 500 \mu\text{g/L}$ .  |
| III.  | Soluble CD25 i.e. (soluble IL-2 receptor) $\geq 2400 \text{U/ml}$ .                      |

## CONCLUSION

FHLH should be included in the differential diagnosis of acute liver failure in neonates and young infants. Because effective treatment is available, adequate diagnostic management leading to early diagnosis is mandatory.

## REFERENCES

- Whaley BF. Familial hemophagocytic lymphohistiocytosis in the neonates. *Adv Neonatal Care*. 2011;11(2):101-7.
- Gurgey A, Unal S, Okur H, Orhan D, et al. Neonatal primary hemophagocytic lymphohistiocytosis in Turkish children. *J Pediatr Hematol Oncol*. 2008;30(12):871-6.
- Woods AG, Woods CW. Hemophagocytic lymphohistiocytosis in the premature neonate: a case study. *Adv Neonatal Care*. 2009;9(6):274-8.
- Suzuki N, Morimoto A, Ohga S, Kudo K, et al. Characteristics of hemophagocytic lymphohistiocytosis in neonates: a nationwide survey in Japan. *J Pediatr*. 2009;155(2):235-8.
- Levendoglu-Tugal O, Alexander V, Parvez B, Lagamma EF. Hemophagocytic lymphohistiocytosis associated with necrotizing Enterocolitis in Premature newborns. *Pediatr Blood Cancer*. 2012; 59(2):315-7.
- Uchiyama A, Kusuda S, Imashuku S, Sakuma I, et al. Fatal hemophagocytic lymphohistiocytosis in extremely-low-birthweight infant. *Pediatr Int*. 2010;52(4):661-3.
- Janka GE, Schneider EM. Modern management of children with haemophagocytic lymphohistiocytosis. *Br J Haematol*. 2004;124(1):4-14.
- Henter JI, Elinder G. Cerebrospinal haemophagocytic lymphohistiocytosis. *Lancet*. 1992;339(8785):104-7.

9. Stepp SE, Dufourcq-Lagelouse R, Le Deist F, Bhawan S, et al. Perforin gene defects in familial hemophagocytic lymphohistiocytosis. *Science*. 1999;286(5446):1957-9.
10. Bas AY, Demirel N, Zenciroglu A, Yarali N, et al. Familial haemophagocytic lymphohistiocytosis in two newborn siblings: a good mimicker of newborn sepsis. *Ann Trop Paediatr*. 2007; 27(3):231-5.
11. Stapp J, Wilkerson S, Stewart D, Coventry S, et al. Fulminant neonatal Liver failure in siblings: probable congenital hemophagocytic lymphohistiocytosis. *Pediatr Dev Pathol*. 2006;9(3):239-44.
12. Parizhskaya M, Reyes J, Jaffe R. Hemophagocytic syndrome presenting as acute hepatic failure in two infants: clinical overlap with neonatal hemochromatosis. *Pediatr Dev Pathol*. 1999;2(4):360-6.
13. Henter JI, Horne A, Aricó M, Egeler RM, et al. HLH-2004: Diagnostic and therapeutic guidelines for hemophagocytic lymphohistiocytosis. *Pediatr Blood Cancer*. 2007;48(2):124-31.
14. Palazzi DL, McClan KL, Kaplan SL. Hemophagocytic syndrome in children: an important diagnostic consideration in fever of unknown origin. *Clin Infect Dis*. 2003; 36(3):306-12.
15. Henter JI, Aricó M, Egeler RM, Elinder G, et al. HLH-94: a treatment protocol for hemophagocytic lymphohistiocytosis. HLH study Group of the Histiocyte Society. *Med Pediatr Oncol*. 1997;28(5):342-7
16. Fischer A, Cerf-Bensussan N, Blanche S, Le Deist F, et al. Allogenic bone marrow transplantation for erythrophagocytic lymphohistiocytosis. *J pediatr*. 1986;108(2):267-70.
17. Arico M, Janka G, Fischer A, Henter JI, et al. Hemophagocytic lymphohistiocytosis. Report of 122 children from the International Registry. FHL Study Group of the Histiocyte Society. *Leukemia*. 1996; 10(2):197-203.
18. Shah AJ, Kapoor N, Cooper RM, Crooks GM, et al. Pre- and post-natal treatment of hemophagocytic lymphohistiocytosis. *Pediatr Blood Cancer*. 2009; 52(1):139-42.
19. Jabodo N, de Graeff-Meeder ER, Cavazzana-Calvo M, Haddad E, et al. Treatment of familial hemophagocytic lymphohistiocytosis with bone marrow transplantation from HLA genetically nonidentical donors. *Blood*. 1997;90(12):4743-8.
20. Baker KS, DeLaat CA, Steinbuch M, Gross TG, et al. Successful correction of hemophagocytic lymphohistiocytosis with related or unrelated bone marrow transplantation. *Blood*. 1997;89(10):3857-63.